

UOT: 617.731-008.6

Əfəndiyeva M.E., Saidova L.X.

## TOKSİK NEYROPATIYA İZOTRETİNOİN TERAPİYASININ NADİR OFTALMOLOJİ AĞIRLAŞMASI KİMİ (KLİNİK HAL)

Akademik Zərifə Əliyeva adına  
Milli Oftalmologiya Mərkəzi,  
Cavadxan küç., 32/15  
AZ1114, Bakı şəh., Azərbaycan

**Korrespondensiya üçün:**  
Əfəndiyeva Mətanət Elton qızı,  
t.ü.f.d., "WET-LAB"  
bölməsinin müdiri,  
Akademik Zərifə Əliyeva adına  
Milli Oftalmologiya Mərkəzi  
E-mail: metinefendi@mail.ru  
[https://orcid.org/  
0009-0007-6551-3084](https://orcid.org/0009-0007-6551-3084)

**İstinad üçün:**  
Əfəndiyeva M.E., Saidova L.X.  
Toksik neyropatiya izotretinoin  
terapiyasının nadir oftalmoloji  
ağırlaşması kimi (klinik hal).  
Azərbaycan Oftalmologiya Jurnalı,  
2026, 18; 1 (56): 00-00.  
(İngilis dilində)

**Müəlliflərin iştirakı:**  
*Tədqiqatın anlayışı və dizaynı:*  
Əfəndiyeva M.E.  
*Materialın toplanması və işlənməsi:*  
Əfəndiyeva M.E.  
*Statistik məlumatların işlənməsi:*  
Əfəndiyeva M.E.  
*Mətnin yazılması:*  
Əfəndiyeva M.E.  
*Redaktə:*  
Saidova L.X.

*Müəlliflər münafiqəyə  
(maliyyə, şəxsi, peşəkar və digər  
maraqları) olmamasını təsdiqləyirlər.*  
Daxil olmuşdur 10.02.2026  
Çapa qəbul olunmuşdur 16.03.2026

### XÜLASƏ

İzotretinoinin (13-cis-retinoic acid) sızanaqların müalicəsində yüksək effektivliyinə baxmayaraq, izotretinoin terapiyası xeyli sayda yan təsirlərlə əlaqələndirilir və bəzən daha az rast gəlinən, lakin klinik cəhətdən daha əhəmiyyətli və potensial olaraq gözlənilməz ağırlaşmalara səbəb ola bilər.

**Məqsəd** – təqdim olunan klinik halda sistemli şəkildə qəbul edilən izotretinoin terapiyasının nadir oftalmoloji ağırlaşması kimi toksik neyropatiyanın inkişaf etdiyini göstərmək.

17 yaşlı gənc bir qız, izotretinoin terapiyasına başladıqdan dörd ay sonra sol gözündə görmə qabiliyyətinin aşağı enməsindən, burun tərəfindən duman və kölgə hiss etdiyindən şikayət edirdi. Oftalmoskopiya: OS – görmə siniri diski qansızma ilə örtülüdür, bəzi yerlərdə izlənilə bilən sərhədlər solğun, foveolyar zonaya qədər uzanan peripapillyar ödem, görmə siniri diskinin ətrafında yumşaq eksudatlar müşahidə edilirdi. Torlu qısa damarları qıvrılmış, venalar gərgin və dolğun idi. Torlu qısa səthində müxtəlif ölçülü çoxsaylı intraretinal qansızmalar qeyd edilirdi. OD — göz dibi normal, patoloji dəyişikliklər yox idi. Sol gözün burun tərəfində görmə sahəsinin 20 dərəcəyə qədər daralması, sağ gözdə isə patoloji dəyişiklik olmadığı müşahidə edilirdi.

Optik koherens tomoqrafiyada (OKT) görmə siniri diskinin və makula nahiyəsinin nəzərəcarpacaq ödemi aşkar edilirdi. Xəstənin müayinəsi zamanı koaquloqramma ilə yanaşı ümumi və biokimyəvi qan analizləri, infeksiyalar üçün qan analizi və angiografiya ilə beyin maqnit rezonans görüntüləməsi (MRT) aparıldı. MRT-də heç bir patoloji dəyişiklik aşkarlanmadı və bütün test nəticələri normal həddə idi. Nevropatoloq, hematoloq və dermatoloq xəstəyə izotretinoin qəbulunu dayandırmaq və sistemli qlükokortikosteroidləri qəbul etməyə başlamasını tövsiyə etdilər. Görünür ki, bu klinik halda izotretinoinin toksik təsirinə son aylarda dərmanın dozasının və müvafiq olaraq yeniyetmənin çəkisinə nisbətə kumulativ dozanın həddinin artması səbəb olmuşdur.

### Yekun

Təqdim olunan klinik hal sistemli izotretinoin terapiyasının nadir oftalmoloji ağırlaşması kimi toksik neyropatiyanın inkişafını göstərir. Dərmanın vaxtında dayandırılması və patogenetik terapiyanın tətbiqi morfoloji dəyişikliklərin tədricən geriləməsinə və görmə funksiyalarının yaxşılaşdırılmasına imkan yaratdı.

**Açar sözlər:** izotretinoin terapiyası, yan təsirlər, toksik neyropatiya, görmə itkisi

Efendiyeva M.E., Saidova L.X.

## TOXIC NEUROPATHY AS A RARE OPHTHALMIC COMPLICATION OF ISOTRETINOIN THERAPY (CLINICAL CASE)

National Ophthalmology  
Centre named after  
Academician Zarifa Aliyeva,  
32/15, Javadkhan str.,  
AZ1114, Baku, Azerbaijan

**For correspondence:**  
Efendiyeva Matanat Elton, PhD,  
Head of WET-LAB Department, the  
National Ophthalmology  
Centre named  
after Academician Zarifa Aliyeva  
E-mail: metinefendi@mail.ru  
[https://orcid.org/  
0009-0007-6551-3084](https://orcid.org/0009-0007-6551-3084)

**For citation:**  
Efendiyeva M.E., Saidova L.X.  
Toxic neuropathy as a rare  
ophthalmic complication of  
isotretinoin therapy (clinical case).  
Azerbaijan Journal of  
Ophthalmology,  
2026, 18; 1 (56): 00-00.

**Authors participation:**  
*Concept and design of investigation:*  
Efendiyeva M.E.  
*Material collection and processing:*  
Efendiyeva M.E.  
*Statistical data processing:*  
Efendiyeva M.E.  
*Spelling text:*  
Efendiyeva M.E.  
*Editing:*  
Saidova L.X.

*The authors confirm that there are  
no conflicts (financial, personal,  
professional and other interests).*

Received 10.02.2026  
Accepted 16.03.2026

<https://>

### SUMMARY

Despite the high efficacy of isotretinoin in the treatment of acne, isotretinoin therapy is associated with a significant number of side effects and can sometimes lead to less frequent, but clinically more significant and potentially unpredictable complications.

**Purpose** – a clinical case demonstrates the development of toxic neuropathy as a rare ophthalmic complication of systemic isotretinoin therapy.

A young girl aged 17 complained of deteriorating vision in her left eye four months after starting isotretinoin therapy. She complained of a foggy feeling and shadow on the nasal side of her left eye. Ophthalmoscopy: OS – optic nerve disc (OND) is covered by hemorrhage, in some places the traceable boundaries are blurred, peripapillary edema extending to the foveolar zone. Soft exudates could be observed around the OND. The retinal vessels are tortuous, the veins are tense and full-blooded. Multiple intraretinal hemorrhages of various size could be noted throughout the retinal surface. OD – the fundus is normal, without pathological changes. A marked narrowing of the visual field of the left eye on the nasal side to 20 degrees could be noted, while the right one with no pathological changes. Optical coherence tomography (OCT) revealed severe swelling of the OND and macular area. During the patient's examination we performed a general and biochemical blood tests along with the detailed coagulogram, a blood test for infections and a brain magnetic resonance imaging (MRI) with angiography. The MRI revealed no pathological changes, and all test results were within normal limits. A neuropathologist, hematologist and dermatologist also consulted the patient with recommendations to stop taking isotretinoin and start taking systemic glucocorticosteroids. Apparently, in our case, an increased dose of the medication in recent months has become the reason for the toxic effect and, accordingly, an excessive cumulative dose relative to the teenager's weight.

### Conclusion

The clinical case presented demonstrates the development of toxic neuropathy as a rare ophthalmic complication of systemic isotretinoin therapy. Timely discontinuation of the medication and administration of pathogenetic therapy made it possible to achieve a gradual regression of morphological changes and improvement of visual functions.

**Key words:** *isotretinoin therapy, side effects, toxic neuropathy, loss of vision*

Isotretinoin (13-cis-retinoic acid), a derivative of retinoic acid, is a powerful medication used to treat severe acne vulgaris. It is believed that the medication reduces the size of sebaceous glands and sebum production, thereby providing treatment for nodular cystic acne, which is predominantly found in adolescents and young adults and is clinically manifested as various skin lesions, including cicatricial facial deformities often leading to severe emotional stress [1, 2, 3].

Despite high efficacy of isotretinoin in acne treatment, a significant number of side effects of the medication, including ophthalmic ones, have been described in the literature. Blepharoconjunctivitis, keratoconjunctivitis sicca, contact lens intolerance, refractive changes, papilledema and retinal dysfunction have been reported. Although the most common ophthalmic side effects include stye, chalazion and dry eye disease, as well as blurred vision and nyctalopia (night blindness), it should also be noted that isotretinoin therapy may lead to less frequent, but clinically more significant and potentially unpredictable complications [1 - 9].

**Purpose** – to present a clinical case demonstrating the development of toxic neuropathy as a rare ophthalmic complication of systemic isotretinoin therapy.

On October 31, 2025, a 17-year-old female patient (weight-53 kg, height-174 cm) came to the National Ophthalmology Centre named after Academician Zarifa Aliyeva with a sharp decrease of vision in her left eye.

For more than 5 years, the teenager has been diagnosed with: OD – moderate myopia (–4.5 D); OS – high myopia (–6.0 D); OU – ocular hypertension. Since the age of 12, there have been intraocular pressure (IOP) fluctuations in the range from 19 to 28 mm Hg, both in open anterior chamber angle and lack of changes in the visual field and OND characteristic of glaucoma. Given the aggravated family history of glaucoma (her father has juvenile glaucoma), planned monitoring has been conducted twice a year, including general and special ophthalmic examination methods.

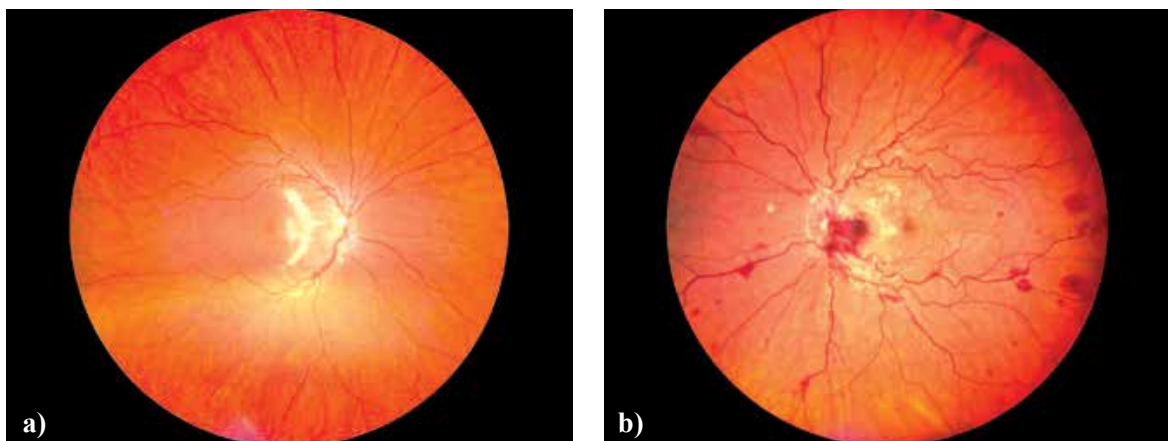
According to the patient, since August 2025, she had been taking isotretinoin 20 mg capsules, with a subsequent increase in the dose up to 40 mg per week; since September the dose had been increased up to 60 mg per week, and since October up to 20 mg daily. Since September, the patient complained of dry eye with subsequent tear replacement therapy prescription. In October, on the first day of increased isotretinoin dose, the patient experienced a transient loss of vision (for about one hour) with visual functions fully restored later on. When the patient came to the clinic, her vision had been impaired for more than 24 hours; she complained of a foggy feeling and a shadow on the nasal side of her left eye.

Vis OD = 0.01 w/c (–4,5 D) = 0.5–0.6;

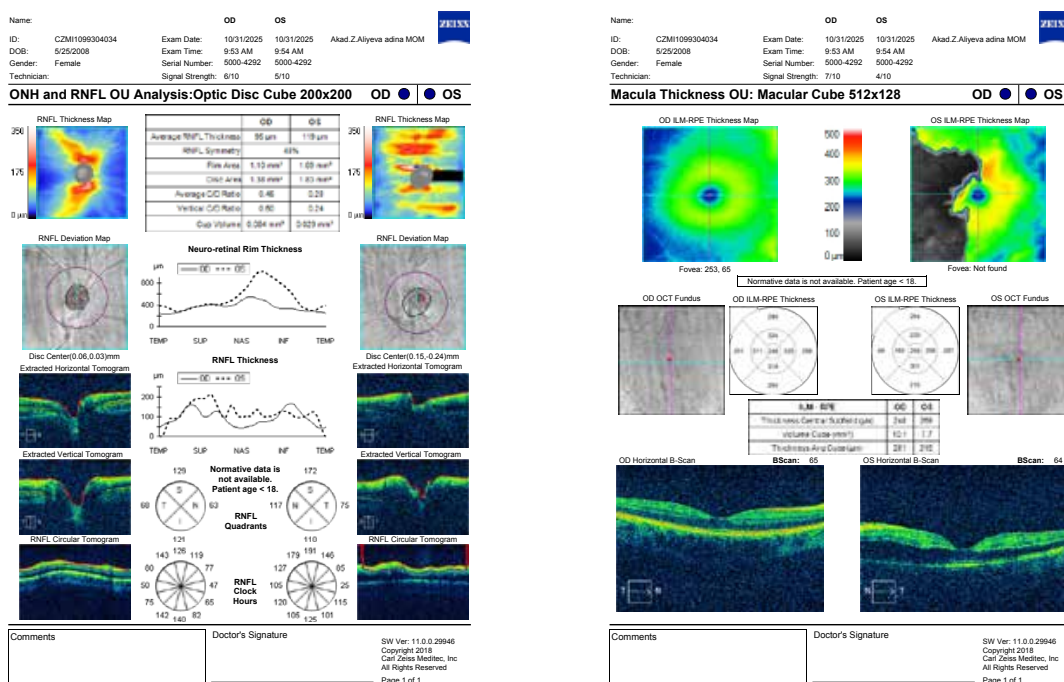
Tn OD = 19.0 mm Hg

Vis OS = 0.03 w/c (–6,0 D) = 0.1;

Tn OS = 20.0 mm Hg



**Figure 1.** The patient's fundus on the first day of observation: a) OD; b) OS



**Figure 2.** OCT of the patient on the first day of observation.

Biomicroscopy detected: OU – conjunctiva was pale pink, cornea was transparent, anterior chamber was of medium depth, pupil was round of medium width. The pupil's reaction of the right eye to the light was lively, of the left eye – sluggish with relative afferent pupillary defect (RAPD). Movement of both eyeballs is to the full extent.

Ophthalmoscopy detected: OS – OND was covered by hemorrhage, in some places the traceable boundaries were blurred, peripapillary edema extending to the foveolar zone. Soft exudates could be observed around the OND. The retinal vessels were tortuous, the veins were tense and full-blooded. Multiple intraretinal hemorrhages of various size could be noted throughout the retinal surface. OD – the fundus was normal, without pathological changes (Fig. 1).

A marked narrowing of the visual field of the left eye on the nasal side to 20° was noted, while the right one showed no pathological changes.

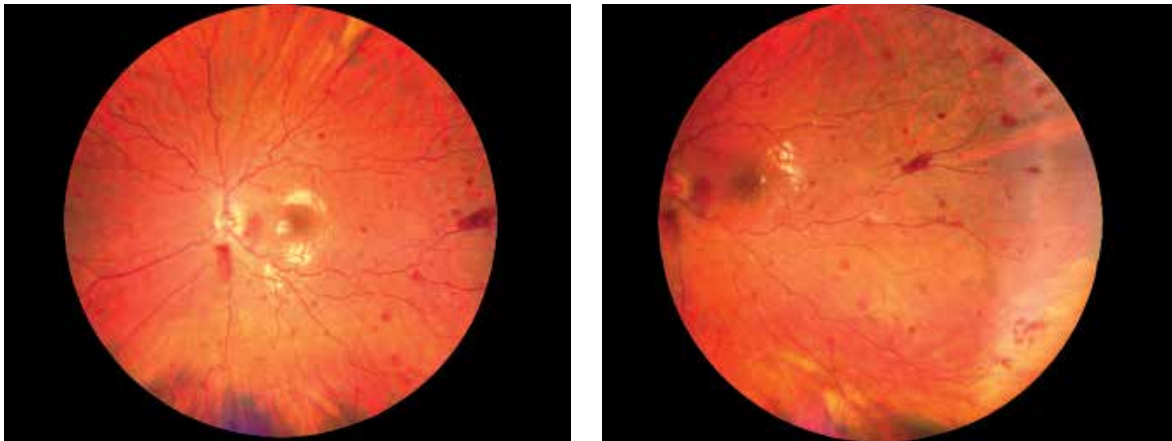
OCT revealed severe swelling of the optic nerve disc and macular area (Fig. 2).

It has recently been suggested that isotretinoin may cause alterations in synaptic

activity and in the propagation of action potentials, resulting in conduction defects within the optic nerve [8]. In the case presented, visual evoked potentials in the right eye were within normal limits, while in the left eye a marked decrease in the amplitude of P100 waves could be observed with preserved latency.

During the patient's examination, we performed a general and biochemical blood tests along with the detailed coagulogram, a blood test for infections and a brain MRI with angiography. The MRI revealed no pathological changes, and all test results were within normal limits. A neuropathologist, hematologist and dermatologist also consulted the patient with recommendations to stop taking isotretinoin and start taking systemic glucocorticosteroids (500 mg/day) and prostaglandin analogue 1 drop per day locally in the evening.

A week later, during the follow-up examination (07.11.25), no positive dynamics were observed. It turned out that the patient did not stop taking isotretinoin as previously suggested. The patient was strongly advised



**Figure 3.** The fundus of the patient's left eye on the 30th day of observation

to stop taking the medication. Two weeks after the start of observation (12.11.25), the patient's condition remained the same, IOP fluctuated between 20 and 24 mmHg.

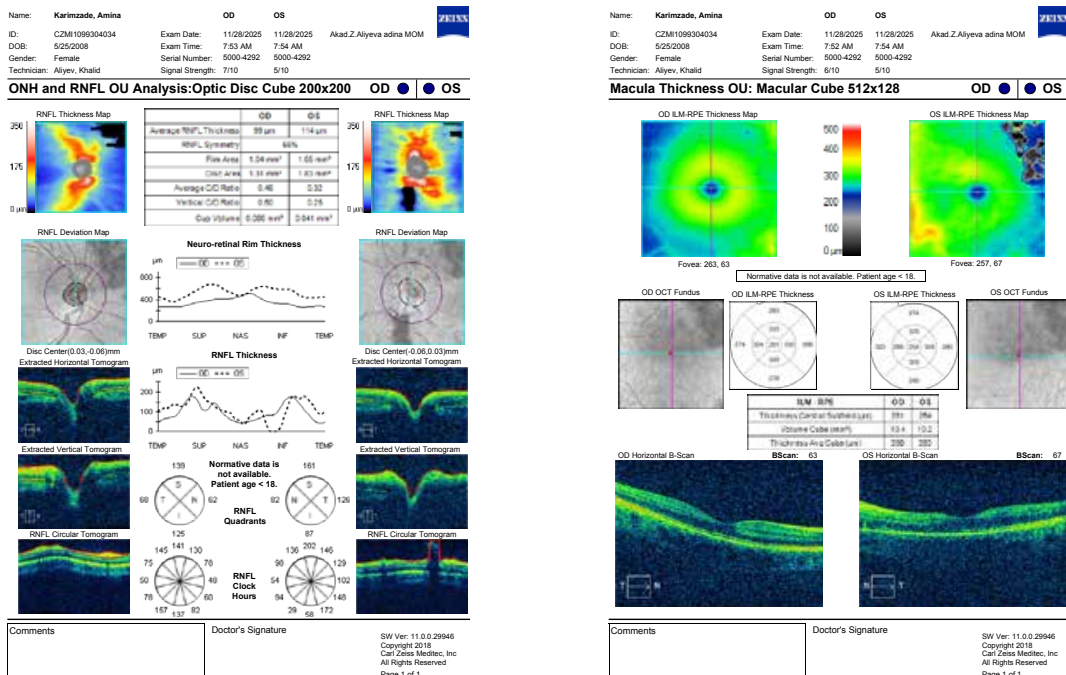
Vis OS = 0.03-0.04 w/c = 0.09 - 0.1  
Tn OU = 22.0 mmHg

One month later (November 28, 2025; on the 30th day of observation), against the background of the therapy, a slight increase in visual acuity was noted.

Vis OS = 0.04 – 0.05 w/c (-6.0 D) = 0.2 – 0.3; Tn OS = 20.0 mmHg

The optic nerve disc was pale pink, peripapillary edema that reached foveolar zone slightly decreased, a fresh hemorrhage appeared near the optic disc on the lower and temporal side, while the number of previous intraretinal hemorrhages decreased (Fig. 3).

OCT proved that the swelling in the area of the optic disc and macula had relatively subsided (Fig. 4).



**Figure 4.** OCT of the patient on the 30th day of observation.

A month and a half later (12.12.25; on the 44th day of the observation), significant positive dynamics were observed.

Vis OD = 0.1 w/c (-4.5 D) = 0.7 – 0.8; Tn OD = 18.0 mmHg  
 Vis OS = 0.06 w/c (-6.0 D) = 0.3 – 0.4; Tn OS = 18.0 mmHg

The examination detected: the OND was pale pink with more distinct borders. A previously observed hemorrhage above the OND had resolved. Macular-foveal reflexes began to clear, and intraretinal hemorrhages were in the process of resorption (Fig. 5).

OCT proved that the swelling in the area of the optic disc and macula had significantly subsided (Fig. 6).

Two and a half months after the start of the observation (15.01.26)

Vis OD = 0.1– 0,2 w/c (-4.5 D) = 0.8 – 0.9; Tn OD = 19.0 mmHg  
 Vis OS = 0.06 w/c (-6.0 D) = 0.7– 0.8; Tn OS = 20.0 mmHg

The optic nerve disc was pale pink with clearly distinct borders. Macular-foveal reflexes were clearly visible, while intraretinal hemorrhages had almost completely resolved, as confirmed by OCT (Fig. 7, Fig. 8).

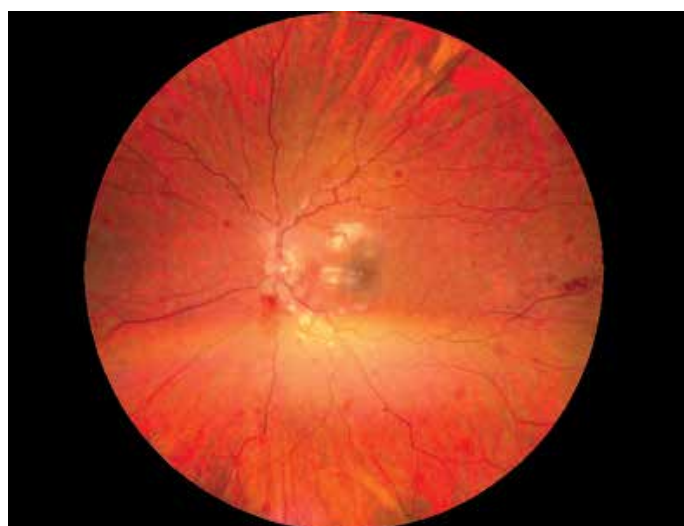

Figure 5. The fundus of the patient's left eye on the 44th day of observation.

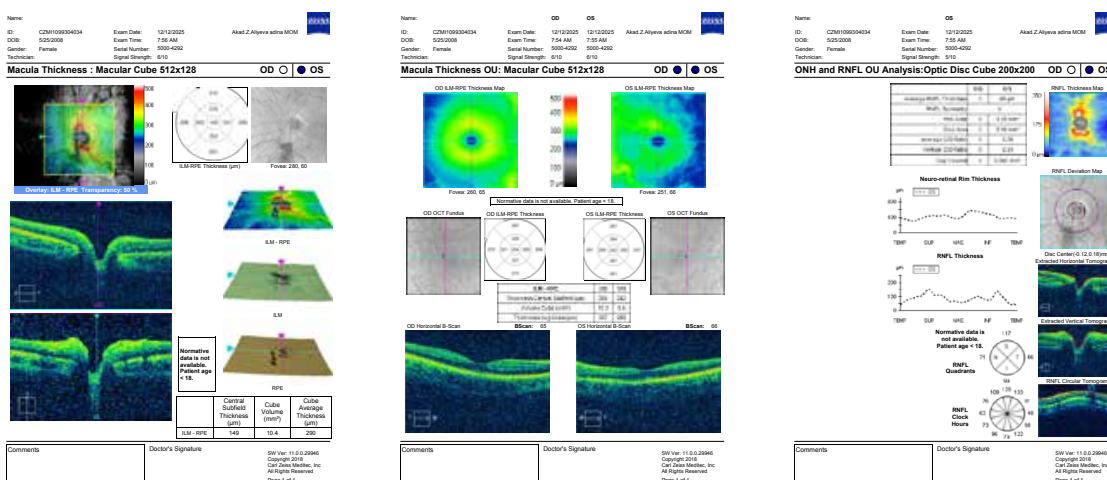


Figure 6. OCT of the patient on the 44th day of observation.

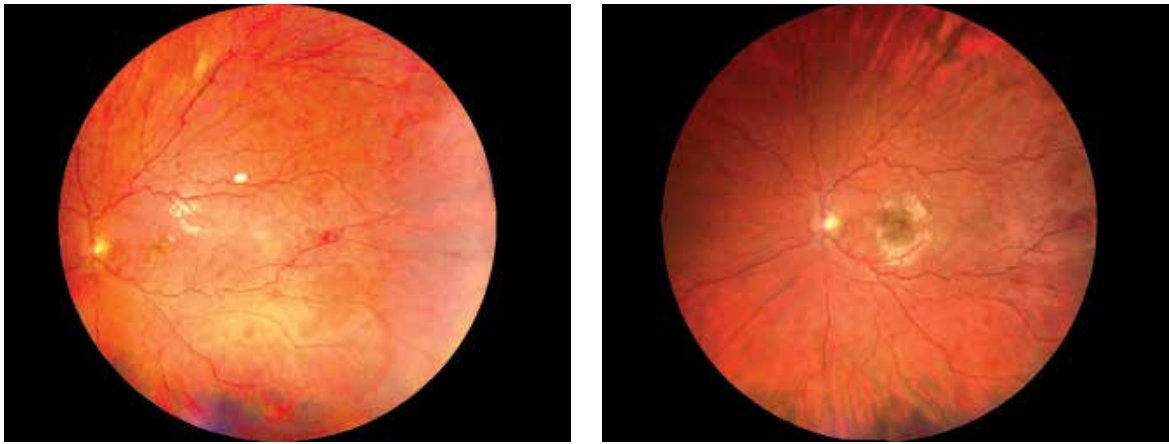


Figure 7. The fundus of the patient's left eye 2.5 months after the start of observations.

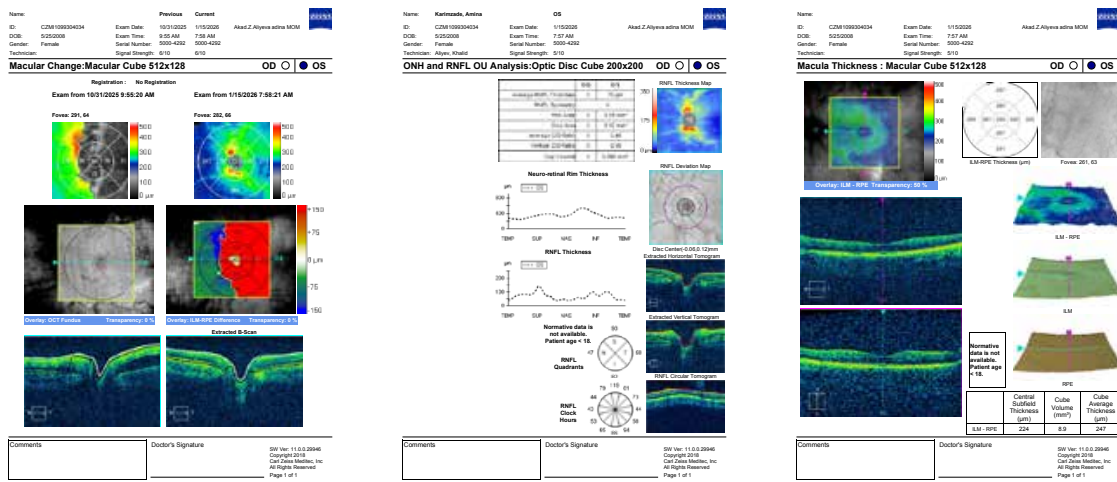


Figure 8. OCT of the patient 2.5 months after the start of the observation.

**Discussion**

The results of the research by Neudorfer M. et al. (2012) demonstrate a reliable connection between systemic isotretinoin therapy and development of clinically significant ophthalmic side effects, with the peak of the increased risk approximately on the fourth month after the start of the therapy, as in this clinical case [2]. According to the literature review by Lamberg O. et al. (2023), visual disturbances may occur as early as on the first days or within the first week of taking the medication [6].

It should also be noted that the high proportion of ophthalmic side effects in female patients reaches 68.1% [2, 3, 7].

According to the data received by Bunya V.Y. et al., up to 98% of patients the

development of side effects while taking isotretinoin 1 mg/kg per day, whereas about 50% of the patients do not report any side effects at doses below 0.25 mg/kg per day [1]. The generally accepted acne treatment regimen involves the administration of isotretinoin at a dose of 0.5 – 1 mg/kg per day until a cumulative dose of 120 – 140 mg/kg is reached, with a total treatment duration of up to 20 weeks [1, 10 - 15]. Apparently, in our case an increased dose of the medication in recent months has become the reason for the toxic effect of the medication and, accordingly, an excessive cumulative dose relative to the teenager's weight. The lack of awareness of both patients (up to 52.2%) and physicians about the potential ophthalmic complications of isotretinoin therapy highlights the need

to increase awareness and interdisciplinary collaboration between dermatologists and ophthalmologists, and need for appropriate clinical monitoring to facilitate early detection and prevention of long-term complications [1, 3, 8]. As follows from the anamnesis, a signal of toxic effects on the retina manifested itself already in the form of short-term loss of vision but lack of awareness resulted in the development of a serious complication.

### Conclusion

The clinical case presented demonstrates development of toxic neuropathy as a rare ophthalmic complication of systemic isotretinoin therapy. Timely discontinuation of the medication and administration of pathogenetic therapy made it possible to gradual regress morphological changes and improve visual functions.

## ƏDƏBİYYAT

### REFERENCE

1. Bunya, V.Y. Ocular Manifestations of Isotretinoin / V.Y.Bunya, V.Rana, M.Chen // – 2024. October; 15. [https://eyewiki.org/Ocular\\_Manifestations\\_of\\_Isotretinoin](https://eyewiki.org/Ocular_Manifestations_of_Isotretinoin)
2. Neudorfer, M. Ocular Adverse Effects of Systemic Treatment With Isotretinoin / M.Neudorfer, I.Goldshtein, O.Shamai-Lubovitz [et al.] // Arch. Dermatol., – 2012. 148(7), – p. 803-808. <https://doi.org/10.1001/archdermatol.2012.352>
3. Roytman, M. Pseudotumor Cerebri Caused by Isotretinoin // Cutis, – 1998. 42, №5, Nov; – p. 399-400.
4. Lee, A.G. Pseudotumor Cerebri after Treatment with Tetracycline and Isotretinoin for Acne // Cutis, – 1995. 55, №3, Mar; – p. 165-168.
5. Isotretinoin dosage medically reviewed by Drugs.com // Last updated on Oct; 27. – 2025. <https://www.drugs.com/dosage/isotretinoin.html>
6. Dosing for Accutane® (Isotretinoin) Treatment. By Treatment Guides // January; 1. – 2007. <https://www.skintherapyletter.com/drug-profiles/dosing/>
7. Cyrulnik, A.A. High-dose isotretinoin in acne vulgaris: improved treatment outcomes and quality of life / A.A.Cyrulnik, K.V.Viola, A.J.Gewirtzman [et al.] // Int. J. Dermatol., – 2012. Sep; 51(9), – p. 1123-1130. <https://doi.org/10.1111/j.1365-4632.2011.05409.x>
8. AlMasoudi, R.M. Patients' Awareness of the Ocular Side Effects of Isotretinoin Therapy: A Study From Saudi Arabia / R.M.AlMasoudi, R.K.Bahaj, A.Kokandi // Cureus, – 2022. April; 30. 14(4), – 24628. <https://doi.org/10.7759/cureus.24628>
9. Lamberg, O. Ocular side effects of systemic isotretinoin – a systematic review and summary of case reports / O.Lamberg, A.Strome, F.Jones [et al.] // Journal of Dermatological Treatment, – 2023. 34, 1, – p. 2213364. <https://doi.org/10.1080/09546634.2023.2213364>
10. Abuallut, I.I. Oral Isotretinoin-Associated Ocular Effects and Risk Factors: A Cross-Sectional Study / I.I.Abuallut, M.Q.Dibaji, A.Assiri [et al.] // Clin. Ophthalmol., – p. 2024. 18, – p. 4041-4052. <https://doi.org/10.2147/OPHTH.S491757>
11. Pérez-Pérez, L. Neuritis óptica probablemente inducida por isotretinoína / L.Pérez-Pérez, J.García-Gavín, F.Allegue [et al.] // Actas. Dermosifiliogr., – 2012. 103, – p. 846-847. <https://doi.org/10.1016/j.ad.2011.10.020>
12. Saraswat, A. Sudden irreversible worsening of myopia with isotretinoin treatment // Indian J. Dermatol. Venereol. Leprol., – 2011. 77, – p. 611-612. <https://doi.org/10.4103/0378-6323.84083>
13. Report of the commission on human medicines isotretinoin expert working group // – 2023. April; 26. <https://assets.publishing.service.gov.uk/media/6448cd0a529eda00123b047d/Isotretinoin-final-CHM-report-26April2023.pdf>
14. Medical information: AKNETRENT® (Isotretinoin) Important safety information including dosage, side effects, and precautions of AKNETRENT // 2024. Mar; 10. <https://elifescience.org/articles/mi-skin-aknetrent>
15. Isotretinoin // <https://en.wikipedia.org/wiki/Isotretinoin>