

UOT: 617.735

Sultanova M.M.*, Ağayeva A.M., Hacı İ.F.

KORNEOSKLERAL YARALANMADAN SONRA TOR QIŞANIN MƏRKƏZİ ARTERİYA VƏ VENASININ KOMBİNƏ OLUNMUŞ OKKLÜZİYASI (KLİNİK HALLAR)

<https://doi.org/10.71110/ajo791020251703546369>

Akademik Zərifə Əliyeva adına
Milli Oftalmologiya Mərkəzi,
Cavadxan küç., 32/15
AZ1114, Bakı şəh., Azərbaycan

Korrespondensiya üçün:
Sultanova Mariyat Məmmədovna,
t.ü.f.d., Akademik Zərifə Əliyevanın
adına Milli Oftalmologiya
Mərkəzinin "Uşaqlarda gözün
patologiyası bölməsi"nin
kiçik elmi işçisi
E-mail: sultmm@hotmail.com
<https://orcid.org/0009-0005-0790-9676>

İstinad üçün:
Sultanova M.M., Ağayeva
A.M., Hacı İ.F. Korneoskleral
yaralanmadan sonra tor qışanın
mərkəzi arteriya və venasının
kombinə olunmuş okklüziyası
(klinik hal).
Azərbaycan Oftalmologiya Jurnalı,
2025, 17; 3 (54): 63-69.
(İngilis dilində)

Müəlliflərin iştirakı:
Tədqiqatın anlayışı və dizaynı:
Sultanova M.M.,
Ağayeva A.M., Hacı İ.F.
Materialın toplanması və işlənməsi:
Sultanova M.M.,
Ağayeva A.M., Hacı İ.F.
Mətnin yazılması:
Sultanova M.M.
Redaktə:
Sultanova M.M.

*Müəlliflər münafiqələri
(maliyyə, şəxsi, peşəkar və digər
maraqları) olmamasını təsdiqləyirlər.*

Daxil olmuşdur 04.03.2025
Çapa qəbul olunmuşdur 19.09.2025

XÜLASƏ

Görmə orqanının travması ilə əlaqəli təcili tibbi yardım şöbəsinə müraciətlərin əsas səbəblərindən biri olaraq qalır.

Məqsəd – dəlib-keçən korneoskleral yaralanma müşahidəsinin təhlili tor qışanın mərkəzi arteriya və venasının kombinə olunmuş okklüziyasının klinik halını təhlil etmək.

38 yaşlı kişi pasiyent aldığı travmadan sonra sol gözündə görmə qabiliyyətinin itirilməsi şikayəti ilə Akademik Zərifə Əliyeva adına Milli Oftalmologiya Mərkəzinə müraciət etmişdir. Pasiyentə müntəzəm oftalmoloji müayinələrlə yanaşı, orbital nahiyyənin kompüter tomoqrafiyası, laborator qan analizləri, elektrokardioqrafiya və fluoroqrafiya təyin edilmişdir. Sol gözün oftalmoloji müayinəsi zamanı yuxarı və aşağı göz qapaqların kəsilmiş yarası, geniş məsafəli korneoskleral dəlib-keçən yaralanması qeyd olunurdu. Cərrahi müdaxilədən sonra göz dibinin müayinəsi zamanı tor qışanın mərkəzi arteriya və venasının kombinə olunmuş okklüziyası müəyyən edilmişdir.

Təqdim olunan müşahidədə göz alması və müdafiə aparatının yaralanması fonunda tor qışanın mərkəzi arteriya və venasının kombinə olunmuş okklüziyasının inkişafının nadir bir klinik halı təsvir edilir. Müvafiq təcili müalicəyə baxmayaraq, xəstənin ləngidilmiş müraciəti əsnasında görmə funksiyası aşağı olaraq qalmışdır; bu vəziyyət tor qışada damar dəyişikliklərinin geri dönməz işemik və struktur fəsadları ilə əlaqələndirilirdi.

Açar sözlər: *görmə orqanının travması, tor qışanın mərkəzi arteriya və venasının kombinə olunmuş okklüziyası*

* Ə.Əliyev adına Azərbaycan Dövlət Həkimləri Təkmilləşdirmə İnstitutu,
Oftalmologiya kafedrası, AZ1012, Bakı şəh., Tbilisi prospekti 3165

Sultanova M.M.*, Aghayeva A.M., Haji I.F.

COMBINED OCCLUSION OF THE CENTRAL RETINAL ARTERY AND VEIN AFTER CORNEOSCLERAL INJURY (CLINICAL CASES)

<https://doi.org/10.71110/ajo791020251703546369>

National Ophthalmology
Centre named after
Academician Zarifa Aliyeva,
32/15, Javadxan str.,
AZ1114, Baku, Azerbaijan

For correspondence:

Sultanova Mariyat Mamedovna,
PhD, junior researcher in
Pediatric Department of National
Ophthalmology Centre named after
Academician Zarifa Aliyeva
E-mail: sultmm@hotmail.com
<https://orcid.org/0009-0005-0790-9676>

For citation:

Sultanova M.M., Aghayeva A.M.,
Haji I.F. Combined occlusion of the
central retinal artery and vein after
corneoscleral injury (clinical case).
Azerbaijan Journal of
Ophthalmology,
2025, 17; 3 (54): 63-69.

Authors participation:

Concept and design of investigation:
Sultanova M.M.,

Aghayeva A.M., Haji I.F.

Material collection and processing:
Sultanova M.M.,

Aghayeva A.M., Haji I.F.

Spelling text:

Sultanova M.M.

Editing:

Sultanova M.M.

SUMMARY

Eye injury remains a frequent reason to go to the emergency.

Purpose – to analyze clinical case of combined occlusion of the central retinal artery and vein (CRAVO) on the background of corneoscleral penetrating trauma.

A 38-year-old man complained of vision loss in his left eye after receiving an injury applied to the NCO named after Academician Zarifa Aliyeva. Routine ophthalmological examinations, computed tomography of the orbital region, clinical and biochemical blood tests, cardiogram, fluorography were prescribed. On examination, an injury of the upper and lower eyelids is noted on the left eye, as well as an extensive penetrating corneoscleral wound. Examination of the fundus after surgical treatment of the wound revealed a combined CRAVO.

The presented case describes a rare clinical condition involving the development of combined occlusion of the central retinal artery and vein against the background of globe and ocular adnexa trauma. Despite appropriate emergency treatment, the patient's delayed presentation resulted in persistently reduced visual function, which was attributed to irreversible ischemic and structural complications caused by vascular changes in the retina.

Key words: *trauma of the organ of vision, combined occlusion of the central retinal artery and vein*

*The authors confirm that there are
no conflicts (financial, personal,
professional and other interests).*

Received 04.03.2025

Accepted 19.09.2025

* Azerbaijan State Institute for Advanced Medical Studies named after A.Aliyev,
Department of Ophthalmology, AZ1012, Tbilisi Avenue-3165, Baku

Ocular trauma remains one of the most common reasons for visiting the emergency department. Worldwide, approximately 55 million patients sustain injuries to the eye and its adnexa each year, with permanent vision loss occurring in 1.6 million cases [1,2,3,6]. Eye injuries are classified as open or closed [7]. The most severe cases are those in which both the anterior and posterior segments are damaged. Vitreoretinal changes and complications rank second after corneal injuries in penetrating globe trauma [8]. Vascular disorders, such as acute occlusion of the central retinal artery and vein arising from trauma, can lead to catastrophic consequences. The delicate structures of the eyeball experience acute deprivation of nutrients and oxygen, compounded by the effects of mechanical tissue damage. Against the background of these combined changes, the process of converting visual images and transmitting signals to the brain is disrupted, and irreversible blindness may occur. Such an outcome is uncommon; the literature describes only a small number of cases of retinal artery and vein occlusion following blunt ocular trauma, and rare reports following open globe injuries [9].

Given the isolated reports in the literature of acute vascular disorders in cases of trauma to the organ of vision, this paper presents a rare clinical case of combined retinal artery and

vein occlusion resulting from a penetrating injury to the cornea and sclera.

Purpose - to present a clinical case of combined occlusion of the central retinal artery and vein following a penetrating injury to the cornea and sclera.

A 38-year-old male patient, A., presented to the Emergency Department of the National Ophthalmology Centre named after Academician Zarifa Aliyeva with complaints of loss of vision in the left eye after a domestic injury caused by shards from a large mirror that had fallen and broken. According to the patient, the incident occurred 48 hours earlier during home repairs. He initially sought care at the local hospital, where sutures were placed on the skin of his cheek. The patient was subsequently referred to the National Ophthalmology Centre named after Academician Zarifa Aliyeva for surgical intervention, arriving two days after the injury. Upon admission, the following investigations were ordered: visual acuity testing, tonometry, biomicroscopy, ophthalmoscopy, orbital computed tomography, biochemical and serological blood analysis, electrocardiography, and fluorography. The patient denied any comorbidities or harmful habits.

Examination findings: Inspection revealed a laceration of the upper and lower eyelids on the left (**Figure 1, a**). Surgical

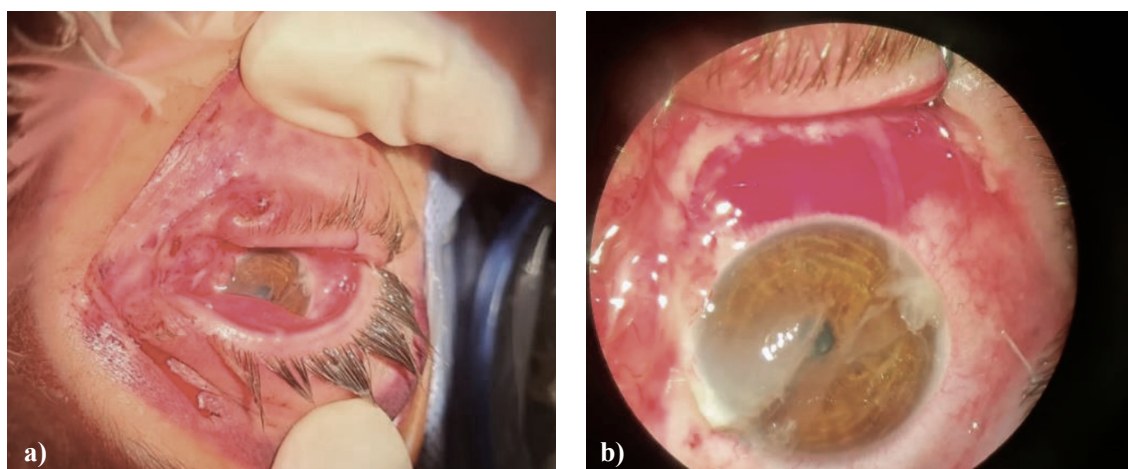


Figure 1. Photographs of the patient A.'s left eye: a) laceration of the upper and lower eyelids; b) penetrating corneoscleral injury.

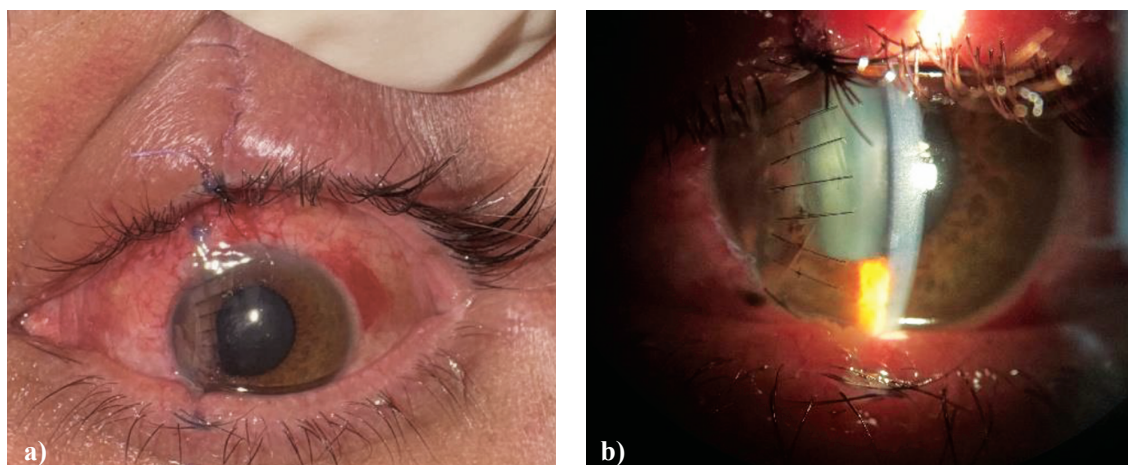


Figure 2. Photographs of patient A.'s left eye on the first day after primary surgical treatment: a) skin sutures are adequate, wound edges are well-adapted and clean; b) corneal edema, sutures clean.

interrupted sutures were noted on the left cheek. The conjunctiva was hyperemic and edematous. There was a penetrating corneoscleral wound starting at the 11 o'clock meridian in the paraoptic corneal zone, initially directed toward the center, then gradually changing direction and crossing the limbus at the 8 o'clock meridian. It can be assumed that the injuring agent (a large fragment of the mirror), upon falling, entered the tissue at an angle of 25–30 degrees, which resulted in good wound adaptation without prolapse of the intraocular contents. The anterior chamber was shallow, with aqueous humor opacification. The pupil was oval in shape, approximately 2 mm in diameter. The lens could not be examined due to the presence of delicate inflammatory exudate covering the pupillary area. The posterior segment was not visualized (**Figure 1, b**). Therefore, assessment of the fundus vessels at the time of admission was not possible.

Visual acuity: OD = 1.0; OS = light perception with correct projection.

The patient underwent primary surgical debridement of the open corneoscleral wound, as well as suturing of the injured eyelids. At the first postoperative examination: OS — skin sutures were adequate, wound edges well-adapted and clean (**Figure 2, a**). The cornea was edematous, the wound was sutured, with no discharge (**Figure 2, b**). The

anterior chamber was of moderate depth, the pupil was round and medically dilated. The lens was transparent.

Fundus findings (left eye): The optic disc was pale, with indistinct margins. Arteries in the super-nasal quadrant were markedly narrowed, with no blood flow visible in the vessels. The retina appeared pale and grayish-milky; in the paramacular area, there were pinpoint hemorrhages, and the macula was bright red, showing the cherry-red spot sign. The veins in the same area were slightly narrowed. In the superotemporal half of the retina, numerous flame-shaped hemorrhages were observed; the veins were dilated, tortuous, and engorged (**Figure 3, a**). Arteries in the superotemporal area were narrowed and elevated above the veins at the crossing points, while the veins were indented beneath the arteries (Salus sign). Optical coherence tomography revealed intraretinal ischemia with serous detachment of the neurosensory retina (**Figure 3, b**). Echobiometry of the eyeball showed thickening in the paracentral retinal area (**Figure 3, c**).

Right eye: The ocular adnexa showed no pathology. The cornea was spherical and clear, the anterior chamber of moderate depth, and the media transparent. **Fundus:** The optic disc was pale pink, with sharp margins and no cupping. The arteries were light red with a more pronounced light reflex (a narrow light

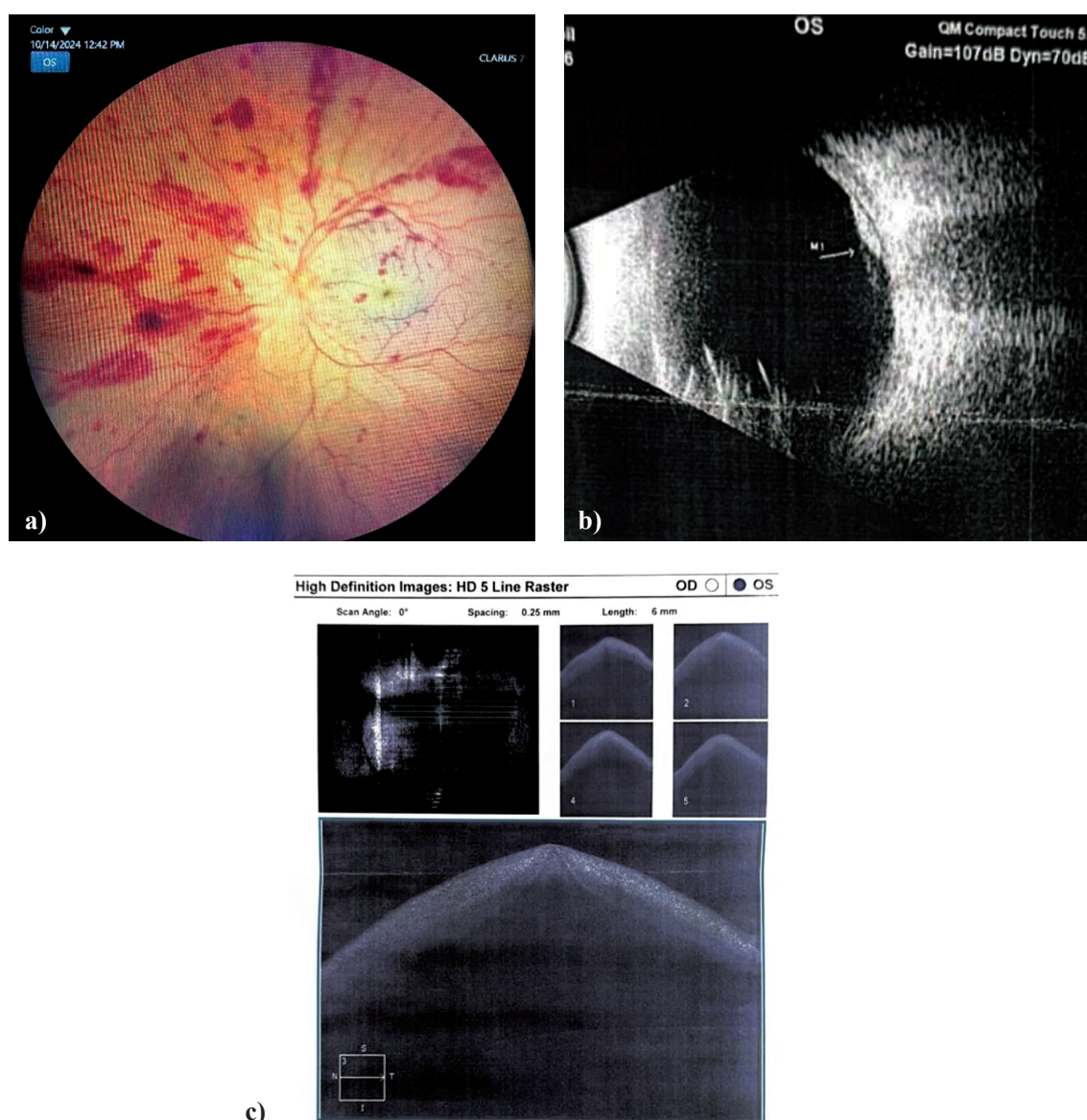


Figure 3. Documentation of fundus changes in the left eye of patient A. on the first day after primary surgical treatment: a) fundus photograph showing numerous flame-shaped hemorrhages, dilated and tortuous veins, cherry-red spot sign, and narrowed arteries; b) B-scan ultrasound showing thickening in the paracentral area; c) optical coherence tomography image (intraretinal ischemia with serous detachment of the neurosensory retina)

column along the center of the vessel), had clear borders, and bifurcated dichotomously. The artery-to-vein ratio was 2/3. The veins were dark red, with a slightly broader and less intense light reflex, and distinct vessel walls. From the optic disc, the vessels radiated outward, curving slightly in the upper and lower quadrants along the arcades of the maculopapillary area. The retina and macular region were without pathology.

Patient's blood test results: Complete

blood count revealed no abnormalities; ESR, C-reactive protein, lipid profile, homocysteine, fibrinogen, platelet aggregation – all within normal limits; coagulation profile – normal.

Discussion

As is known, combined CRAVO is a relatively rare condition that leads to severe visual impairment. A recognized precipitating factor is compression of the orbital contents by a traumatic agent, resulting in stretching

of the blood vessels. This, in turn, causes focal vasospasm and stretching of the retinal vessels. As a result, endothelial damage occurs, leading to thrombus formation and vascular occlusion with subsequent retinal ischemia [9]. In cases where the patient has concomitant somatic vascular pathology such as hypertension, diabetes mellitus, or other vascular diseases, the risk of developing this complication is significantly higher. In our case, the condition developed against the background of a penetrating injury. The corneal scar that forms after such trauma is, by itself, often a cause of reduced vision. In the case described, the corneal condition allowed a full examination of the fundus within the first 10 hours after primary surgical treatment. The vascular disturbances that developed due to the trauma also contributed to vision loss. The degree and nature of visual impairment in such patients are comparable to CRAVO. Many reports indicate that visual acuity often decreases to counting fingers at close range or even to light perception only [10 – 14]. Some researchers note that relatively good visual acuity can be preserved, depending on the degree and duration of ischemia caused by CRAVO, provided that appropriate therapy is initiated within the first minutes of its onset [14 – 16]. In our patient, along with the penetrating corneoscleral injury, a contusion injury was also present. The traumatic agent (a mirror fragment) entered the eye area, cutting the eyelids, cornea, and sclera, while simultaneously delivering an impact. The sudden change in pressure, compression, and stretching of the globe and its vessel walls caused vascular wall damage, ultimately leading to the development of CRAVO. Without doubt, a timely diagnosis would have enabled better therapeutic outcomes; however, the patient presented to the specialized trauma unit only on the second day after injury. As is known, CRAVO treatment should be initiated within the first minutes, while late therapy generally yields no significant results.

The patient was prescribed appropriate therapy to stabilize the post-traumatic condition

(antibiotic therapy, anti-inflammatory therapy, and resorptive medications). Since more than 24 hours had passed after the development of combined retinal artery and vein occlusion, the treatment strategy focused on the use of resorptive agents to reduce the number and intensity of retinal hemorrhages, along with hormonal therapy and topical nonsteroidal anti-inflammatory drugs. At the one-month follow-up, visual acuity had improved to 0.01, intraocular pressure was within normal limits, and the eye was quiet. Fundus examination showed a reduction in the number of hemorrhages due to resorption. The visual prognosis was deemed poor, and the patient remained under dynamic observation. At the three-month follow-up, early lens opacity was noted, which hindered further examination. Visual acuity at that time was 0.02 (despite the developing cataract). Fundus appearance remained unchanged. Phacoemulsification of the cataract was recommended for diagnostic purposes.

Conclusion

This article describes a rare case of combined CRAVO following open globe injury. Despite appropriate emergency treatment, the patient's visual function remained poor, which was due to vascular changes in the retina. One of the undeniable reasons for such an outcome was the delayed presentation to a specialized hospital. Typically, patients with ocular trauma first seek help at their local medical facility, often after waiting several days. They then receive treatment locally, which results in further loss of time. Only after this are they referred to a specialized ocular trauma department. Unfortunately, in the present case, such a delay led to poor functional results. Early presentation to a specialized hospital after ocular injury allows for a comprehensive diagnostic evaluation and timely, appropriate treatment, increasing the likelihood of achieving better outcomes.

ƏDƏBİYYAT

REFERENCE

1. Намазова, И.К. Проблема механической травмы органа зрения у контингента пациентов старшей возрастной группы и ее особенности // *Azərbaycan Oftalmologiya Jurnalı*, – 2014. 15, – s. 38-44.
2. Намазова, И.К. К анализу неблагоприятных исходов механической травмы органа зрения в группе пациентов старшего возраста // *Azərbaycan Oftalmologiya Jurnalı*, – 2014. 14, – s. 91-96.
3. Bayramova, H.O. Azərbaycan Respublikasında yetkin əhali arasında görmə orqanı zədələnmələrinin rastgəlmə tezliyinin xüsusiyyətlərinin öyrənilməsi // *Azərbaycan Oftalmologiya Jurnalı*, – 2024. 2(49), – s. 3-8.
4. Султанова, М.М. Вторичная глаукома как результат травмы / М.М.Султанова, А.М.Агаева // *Azərbaycan Oftalmologiya Jurnalı*, – 2023. 2(45), – s. 87-94. <https://doi.org/10.30546/2709-4634.2023.45.0781>.
5. Matthew, F.G. Programme for the Prevention of Blindness and Deafness / World Health Organization / – Geneva, – Switzerland // Overview of eye injuries in the emergency department, Aug; 26. – 2024.
6. Офтальмология / Национальное руководство / Под. ред. С.Э.Аветисова, Гэотар-Медиа, – 2008. – с. 1017.
7. Kuhn, F. Intraocular foreign bodies. In: Kuhn F, Pieramici D, editors. Ocular Trauma: Principles and Practice / F.Kuhn, V.Mester, R.Morris // Thieme Medical Publishers, – USA: – 2002. <https://doi.org/10.1055/b-002-51011>
8. Lee, M.W. Optic disc laceration with combined retinal artery and vein occlusion following penetrating injury / M.W.Lee, S.Y.Lee, S.G.Ong // *Clin. Experiment Ophthalmol.*, – 2007. Jul; 35(5), – p. 486-488. <https://doi.org/10.1111/j.1442-9071.2007.01518.x>
9. Song, P. Global epidemiology of retinal vein occlusion: a systematic review and meta-analysis of prevalence, incidence, and risk factors / P.Song, Y.Xu, M.Zha [et al.] // *J. Glob. Health*, – 2019. 9, – p. 1020-1030. <https://doi.org/10.7189/jogh.09.010427>
10. Мошетьова, Л.К. Окклюзия сосудов сетчатки: генетические предикторы развития и особенности течения / Научный доклад об основных результатах подготовленной научно-квалификационной работы (диссертации) / – Москва, – 2017.
11. Akhlaghi, M. Acute vision loss in systemic lupus erythematosus: bilateral combined retinal artery and vein occlusion as a catastrophic form of clinical flare / M.Akhlaghi, B.Abtahi-Naeini, M.Pourazizi // *Lupus*, – 2018. 27(6), – p. 1023-1026. <https://doi.org/10.1177/0961203317727602>
12. Wang, H. Clinical Features of Combined Central Retinal Artery and Vein Occlusion / H.Wang, Y.Chang, F.Zhang, [et al.] // *J. Ophthalmol.*, – 2019. Oct; 9. – p. 7202731. <https://doi.org/10.1155/2019/7202731>
13. Lee, S. Combined central retinal artery and vein occlusion with ischemic optic neuropathy after COVID-19 vaccination / S.Lee, K.K.Sankhala, S.Bose [et al.] // *Int. Med. Case Rep. J.*, – 2022. 15, – p. 7-14. <https://doi.org/10.2147/IMCRJ.S328931>
14. Vallée, J.N. Combined central retinal arterial and venous obstruction: emergency ophthalmic arterial fibrinolysis / J.N.Vallée, M.Paques, A.Aymard [et al.] // *Radiology*, – 2002. 223, №2, – p. 351-359. <https://doi.org/10.1148/radiol.2232010423>
15. Sowka, J.W. Atypical retinal vaso-occlusion with structural and functional resolution / J.W.Sowka, L.A.Vollmer, M.Au // *Optometry and Vision Science*, – 2015. 92, №1, – p. 6-11. <https://doi.org/10.1097/OPX.0000000000000446>
16. Lima, V.C. Intravitreal triamcinolone and bevacizumab therapy for combined papillophlebitis and central retinal artery occlusion / V.C.Lima, T.S.Prata., G.Landa [et al.] // *Retinal Cases & Brief Reports*, – 2010. 4, №2, – p. 125-128. <https://doi.org/10.1097/ICB.0b013e3181ad3957>